

Fall Incident on October 4, 20XX

From March 21, 20XX until September 27, 20XX, Ms. Doe had multiple office visits and sought treatment for right renal cyst, chest mass and lower back pain.

On October 04, 20XX, Joe Doe was at the service station building and while she was walking, she stepped on a floor mat that was covering a large hole/uneven surface. She twisted her right ankle and fell landing on her left side. (PDF Ref: 2360-2362)

On the same day, Ms. Doe presented to Samantha Straight, PA-C at FS Urgent Care for the complaints of pain in her neck, chest wall, left ribs, left shoulder and right ankle/foot. Her neck pain was radiating to her left shoulder. On examination, she had tenderness in the muscles of her neck, chest and right ankle. She also had painful range of motion in her neck and right ankle. X-rays of her neck, left ribs, left shoulder, right ankle, and right foot were obtained. The X-ray of her right ankle and foot revealed plantar calcaneal enthesophyte. She was diagnosed with pain in her chest, left shoulder, right ankle, and right foot along with myalgia. Naproxen and Flexeril were prescribed for pain relief. She was advised to take rest, apply ice packs to the affected areas, perform compression and elevation, and wear ace wrap and orthoglass short leg splint to her right ankle. (PDF Ref: 2360-2362)

On the following day (October 05, 20XX), Ms. Doe returned to Samantha Straight, PA-C at FS Urgent Care for the complaints of severe pain in her right ankle and foot. Diagnostic studies of her neck, left ribs, left shoulder, right ankle, and right foot were discussed. CTs of her right ankle and right foot were ordered. She was advised to take rest, apply ice packs to the affected areas, and perform compression and elevation. She was also advised to continue taking Naproxen and Flexeril for pain relief. (PDF Ref: 2363-2364)

On the same day, Dixon Gilbert, M.D., obtained CTs of her right ankle and right foot. The CT of her right ankle revealed small plantar and Achilles enthesophytes of the calcaneus. A CT of her right foot revealed a 3 mm bone island within the distal tibia and a small accessory 4 mm ossicle medial to the navicular and talus bones. There was a 6 mm accessory ossicle lateral to the cuboid bone along with a moderate inferior calcaneal enthesophyte. [2373-2375]

On October 07, 20XX, Ms. Doe presented to Robert Hehre, PA-C at FS Urgent Care for the complaints of pain in her right ankle. She was wearing a brace to her right ankle. She was advised to wear the splint for one more week, for further support and to apply ice packs to the affected areas. She was also advised to continue taking Naproxen and Flexeril. [2365-2366]

On October 11, 20XX, Ms. Doe presented to Janet Thorley, FNP-BC at FS Urgent Care for the complaints of spasm in her neck, facial numbness and pain in her left ribs and hip. Prednisone was prescribed and an MRI of her neck was ordered. She was advised to continue taking Naproxen and Flexeril for pain relief. [2367-2368]



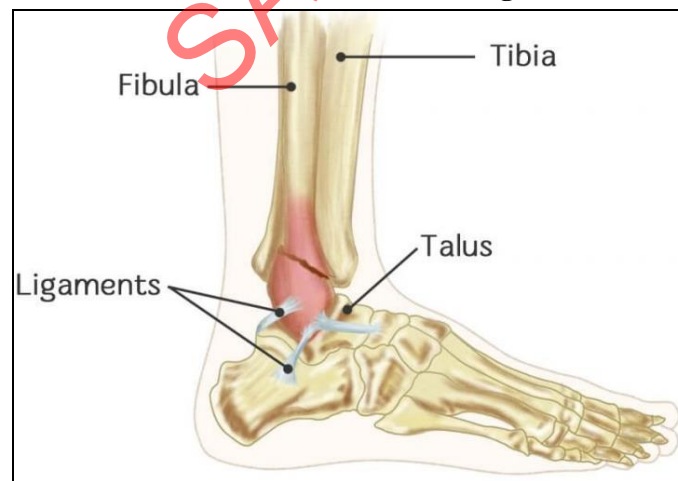
Joe Doe

DOB: mm/dd/yyyy

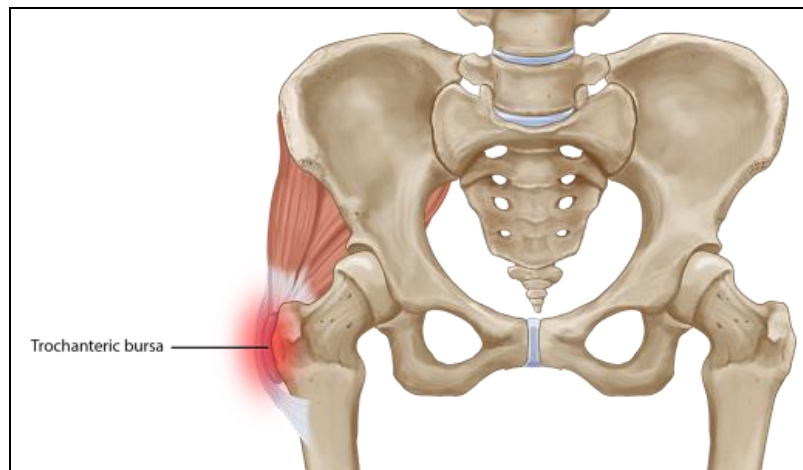
On October 19, 20XX, Ms. Doe presented to Katherine Jett, M.D., at BH Medical Group for the complaints of pain in her neck, left shoulder and left hip. She had numbness and tingling sensation in the left side of her face, neck and arm. She was unable to bear weight on the back of her right foot. She was upset that she had lost her job as a caregiver due to her injuries. On examination, she had tenderness and limited range of motion in her neck. She was diagnosed with cervical radiculopathy. An MRI of her cervical spine was ordered. She was referred to an orthopedic surgeon and advised to wear a walking boot. A follow-up was recommended in four weeks. [1017-1027]

On October 28, 20XX, Ms. Doe presented to Sarah Clark, APRN at BH Medical Group for the complaints of pain in her left hip and right ankle. Her left hip pain aggravated while sitting and ambulating. She attempted to walk by applying toe-touch pressure to her right ankle, but she was unable to tolerate the pain due to increased throbbing sensation. On examination, she had swelling in her right ankle. She also had tenderness, limited range of motion and decreased muscle strength in her right ankle and left hip. Orthopedic tests such as Faber, Ober, and Fadir tests were all positive. X-rays of her left hip and right ankle were obtained. The X-ray of her right ankle revealed nondisplaced fracture at lateral malleolus and the X-ray of her left hip revealed normal findings. She was diagnosed with left greater trochanteric bursitis and closed nondisplaced fracture of lateral malleolus of right fibula. A corticosteroid injection was administered to her left hip. She was advised to continue using walking boot for ambulation. She was recommended to receive an injection to her hip under fluoroscopy, if her symptoms failed to improve with the corticosteroid injection. A follow-up was recommended in three weeks with a repeat X-ray of her right ankle. [1292-1306]

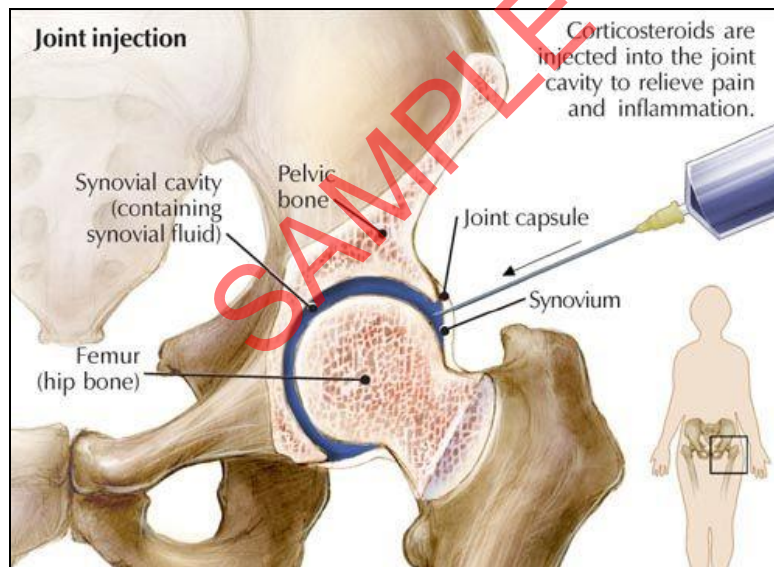
Fracture of lateral malleolus of right fibula



Left Greater Trochanteric Bursitis

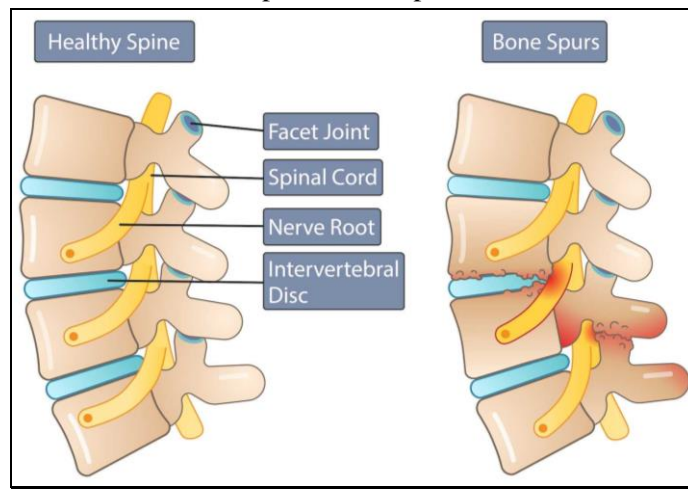


Corticosteroid Injection



On November 05, 20XX, Ms. Doe presented to LL Diagnostic Center and Open MRI, where Robert Pope, D.O., obtained an MRI of her neck. The study revealed straightening of the normal cervical lordosis and scattered cervical chain lymph nodes. There was a spur disc complex and hypertrophic uncovertebral joints at C3-C4 level. There was a spur disc complex and hypertrophic uncovertebral joints at C4-C5 level with a 9.5 mm central canal narrowing and narrowing of the left neural foramen. There was a spur disc complex asymmetric to the left and hypertrophic uncovertebral joints with 7.5 mm central canal narrowing at C5-C6 level and 7 mm central canal narrowing at C6-C7 levels. Hypertrophic uncovertebral joints were also seen at C7-T1. [1045-1047]

Spur disc complex



On November 16, 20XX, Dr. Jett reviewed the findings of her cervical MRI and referred Ms. Doe to a spine surgeon for further evaluation. [1051]

On November 18, 20XX, Ms. Doe had a follow-up visit with Sarah Clark, APRN at BH Medical Group for the complaints of pain in her right ankle. On examination, she had tenderness and limited range of motion in her right ankle. An X-ray of her right ankle was obtained which revealed healed distal fibula fracture. She was advised to start using tennis shoe for ambulation. She was advised to use lace-up ankle brace and begin physical therapy, if she continued to have pain in her right ankle. [1311-1315]

On the same day, Ms. Doe was seen by Dr. Jett at BH Medical Group for the complaints of pain and stiffness in her neck. Her pain aggravated whenever she looked down at her phone. On examination, she had tenderness and limited range of motion in her neck. She was diagnosed with cervical spinal stenosis, sprain of deltoid ligament of her right ankle, closed non-displaced fracture of lateral malleolus of right fibula with routine healing and insomnia. Flexeril and Valium were prescribed for pain control. She was recommended to begin physical therapy and consult a spine surgeon for further evaluation. A follow-up was recommended in a month. [1058-1068]

On November 22, 20XX, Ms. Doe had a mammogram at NW and Children's Hospital. [3219-3228]

On November 29, 20XX, Ms. Doe returned to Sarah Clark, APRN at BH Medical Group for the complaints of increased pain in her right ankle and foot. Her right ankle pain increased with all ambulatory activities. An X-ray of her right ankle was obtained which revealed healing of distal fibula fracture. She was diagnosed with sprain of her right ankle. Prednisone was prescribed and she was advised to begin physical therapy for her right ankle pain. A follow-up was recommended in four weeks. [1324-1332]

Joe Doe

DOB: mm/dd/yyyy

On November 30, 20XX, Ms. Doe presented to Nancy Newman, M.D., at NN Healthcare for the complaints of tenderness and swelling in her left breast. She was concerned that her tenderness was due to the trauma that occurred on October 4, 20XX. On examination, she had tenderness in her left ribs. She was diagnosed with costochondritis, breast tenderness and trauma to her breast. Dr. Newman stated that the tenderness was due to costochondritis which could be a result of trauma to her ribs and it would take some time to heal. [3229-3238]

On December 12, 20XX, Ms. Doe presented to Carroll County Memorial Hospital, where Mark Simmons, PT examined her for an initial physical therapy evaluation. She complained of pain in her right ankle that was aggravated by prolonged sitting, standing, climbing stairs and walking up hills. She rated the severity of her pain as 3/10 on a pain scale. On examination, she had impaired joint mobility, motor function, and muscle performance. She also had decreased range of motion in her right ankle associated with localized inflammation. Her rehabilitative potential was excellent. She performed therapeutic exercises and hot/cold packs were applied. She was advised to continue receiving physical therapy, two times a week for four weeks. [2344-2348]

From December 20, 20XX until December 30, 20XX, Ms. Doe received physical therapy at Carroll County Memorial Hospital for the pain in her right ankle. Her treatment was comprised of therapeutic exercises and therapeutic procedures. On December 30, 20XX, Ms. Doe was advised to continue home exercise program and was discharged from care. [2351-2352]

On January 10, 20XX, Ms. Doe presented to Sara Seifert, PA-C at BH Medical Group for the complaints of headaches and pain in her neck. She rated the severity of her neck pain as 7/10 on a pain scale. An MRI of her neck dated November 5, 20XX was reviewed. She was diagnosed with cervical spinal stenosis. Non-operative treatment options were discussed. She was advised to attend physical therapy sessions, two to three times a week for four weeks for her neck pain. [1096-1104]

On January 13, 20XX, Ms. Doe presented to BB Health LaGrange, where Christine Charbonneau, PT examined her for an initial physical therapy evaluation. She complained of pain in her neck along with joint stiffness, headache and difficulty with daily activities. She had constant pain in her neck since the fall incident. She rated the severity of her pain as 4-6/10 on a pain scale. Her pain aggravated with performing activities such as looking down, prolonged sitting, using her phone, reading, turning her head and while driving and sleeping. She was unable to return to her job as a caregiver and she had to quit an office job due to increased symptoms while reading and looking down. On examination, she had an abnormal posture and limited range of motion in her neck. She also had functional limitation when she tried to perform certain activities. Her treatment was comprised of therapeutic procedure, ultrasound and application of hot/cold packs. She was advised to continue receiving physical therapy, two times a week for four weeks which consisted of cervical traction, electrical stimulation, therapeutic procedure, manual therapy, application of hot/cold packs and ultrasound. [1137-1150]

From January 18, 20XX until January 31, 20XX, Ms. Doe received physical therapy from Christine Charbonneau, PT at BB Health LaGrange for the pain in her neck. She had purchased a cervical

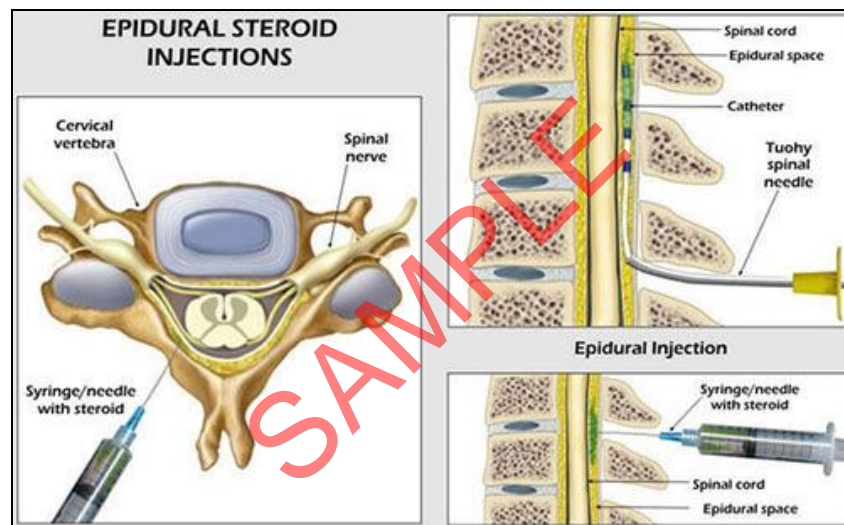


Joe Doe

DOB: mm/dd/yyyy

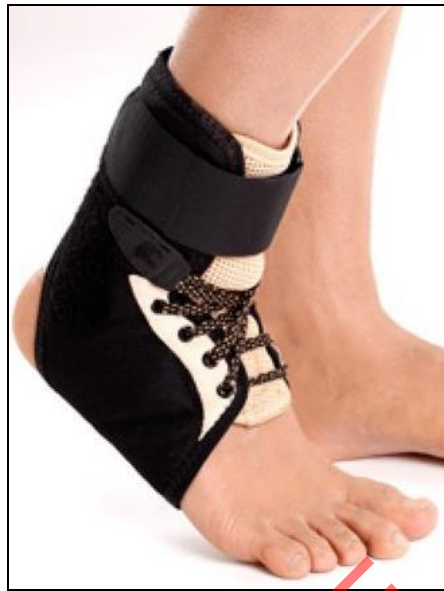pillow and despite using it she continued to have pain in her neck. Her treatment was comprised of therapeutic procedure, application of moist heat, electrical stimulation, manual therapy and ultrasound. On January 31, 20XX, Ms. Doe was advised to use home TENS unit and perform cervical stretches at home. She was recommended to follow-up with her physician and was discharged from care. [1171-1182, 1192-1204, 1213-1225, 1234-1244, 1253-1263, 1272-1283]

On February 03, 20XX, Ms. Doe returned to Sara Seifert, PA-C at BH Medical Group for the complaints of persistent pain in her neck. Her neck pain radiated to her left shoulder. She continued to have pain in her neck despite receiving physical therapy. She wanted to discuss epidural and other treatment options for pain relief. She was recommended to receive cervical epidural steroid injection to her neck. She was advised to consider CT myelogram, if she continued to have pain even after receiving epidural injection. A follow-up was recommended in six weeks. [1118-1135]



On May 09, 20XX, Ms. Doe had a follow-up visit with Sarah Clark, APRN at BH Medical Group for the worsening pain in her right ankle especially when trying to ambulate. She had been taking Ibuprofen multiple times a day for pain relief. On examination, she had decreased range of motion and decreased muscle strength in her right ankle. An X-ray of her right ankle was obtained and reviewed. She was diagnosed with acute right ankle pain. A lace-up ankle brace was provided, and she was advised to wear it for four weeks. She was recommended to perform home strengthening and stretching activities and take Naproxen 500 mg for pain relief. She was advised to consider an MRI of her right ankle and a consultation with an ankle specialist if she continued to have symptoms in her right ankle. [1338-1346]

Lace-up Ankle Brace



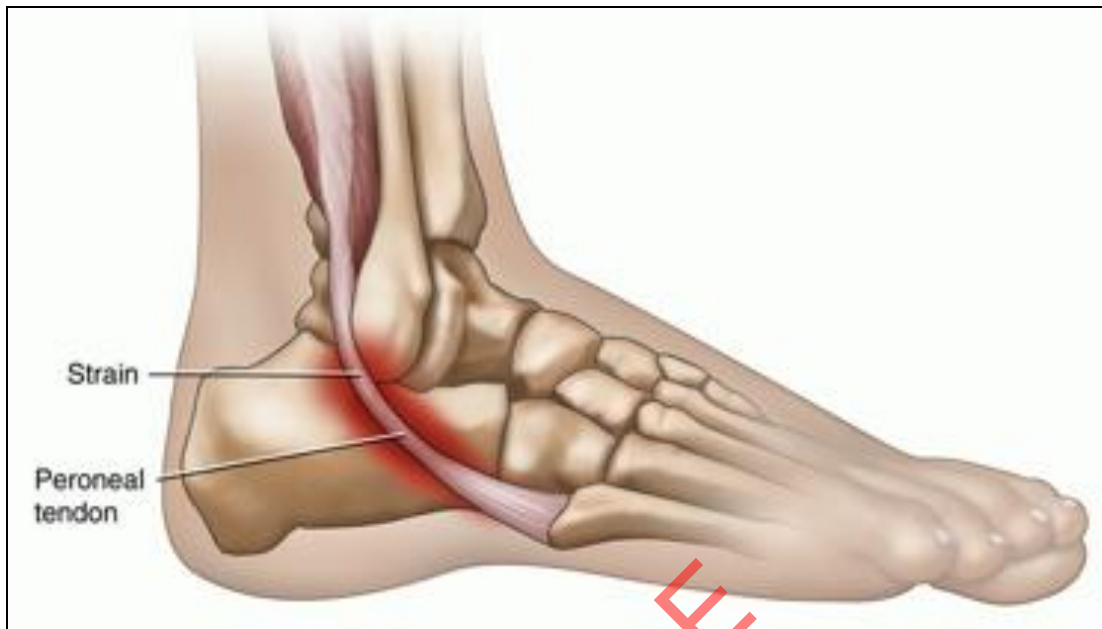
On May 23, 20XX, Ms. Doe had a telephone conversation with Ebony Watters, MA and stated that she had increased pain and stiffness in her neck after receiving epidural steroid injection on May 18, 20XX. [1425]

On May 26, 20XX, Ms. Doe returned to Sara Seifert, PA-C at BH Medical Group. She had increased pain in her neck and left scapular region after receiving epidural steroid injection. Decadron was prescribed. As Ms. Doe continued to have symptoms, she was recommended to have a CT myelogram with flexion and extension X-rays and a consultation with Dr. Reiss for further treatment. She was advised to follow-up with Dr. Reiss after obtaining the radiology tests. [1359-1364]

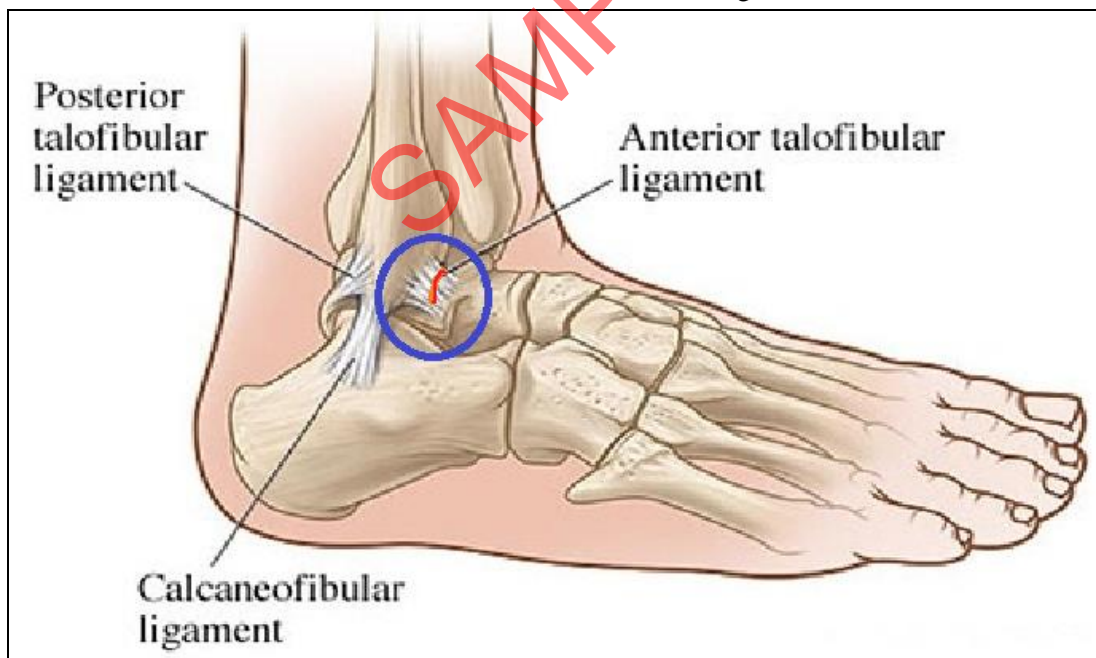
On May 30, 20XX, Ms. Doe had a telephone conversation with Kevin Hall, MA. She stated that she would like to cancel her myelogram and proceed with second epidural steroid injection. [1440]

On June 01, 20XX, Ms. Doe presented to NN Diagnostic Center, where Alan Northington, M.D., obtained an MRI of her right ankle. The study revealed mild tenosynovitis of the peroneus longus tendon below the lateral malleolus at the lateral hind foot, chronic low-grade partial tear of the anterior talofibular ligament, and a small chronic osteochondral lesion of the medial talar dome, likely due to an overlying occult small cartilage defect. [1671-1673]

Peroneal Tenosynovitis



Partial Tear of Anterior Talofibular Ligament



On June 05, 20XX, Ms. Doe had a follow-up visit with Sarah Clark, APRN at BH Medical Group for the constant pain in her right ankle. An MRI of her right ankle was reviewed. She was diagnosed with right peroneal tenosynovitis. She was recommended to have a consultation with a foot/ankle specialist for further evaluation and treatment. [1365-1378]

Joe Doe

DOB: mm/dd/yyyy

On the same day, Ms. Doe had a telephone conversation with Kara Mattingly, MA. She had numbness in the fingers of her left hand after receiving the second cervical epidural steroid injection on June 1, 20XX. She continued to have numbness in her left hand and shooting pain in her right arm. An MRI of her neck was ordered, and she was advised to follow-up with Dr. Reiss. [1441-1442]

On June 08, 20XX, Ms. Doe presented to LL Orthopaedic Clinic, where John Lewis, M.D., examined her for the complaints of pain in her right ankle. Her right posterior lateral ankle pain extended to the retro-fibular region and to the lateral hind foot. She rated the severity of her pain as 5/10 on a pain scale. She continued to have persistent symptoms despite receiving conservative treatment such as medications, physical therapy, and splinting. On examination, she had swelling, tenderness and decreased strength in her right ankle. An X-ray of her right ankle was obtained which revealed reduced talofibular articulation. She was diagnosed with right ankle peroneal tendonitis. Diagnostic studies of her right ankle were reviewed. She did have some persistent pain over her peroneal tendons with MRI of right ankle showing moderate tenosynovitis. She was frustrated about having significant right lateral ankle pain for nearly a year. Dr. Lewis stated that Ms. Doe should try one more round of conservative treatment prior to discussing possible surgery to address her peroneal tendinitis. She was advised to continue taking Naproxen and begin physical therapy, two times for a week for eight weeks to work on peroneal tendon stretching, strengthening, as well as gastrocnemius stretching. She was also recommended to wear ankle brace and follow-up in four to five weeks. [2277-2283]

On June 09, 20XX, Ms. Doe presented to Eric Schneeberger, M.D., at TT Health Systems-Carrollton Main for the complaints of anxiety. She had a fall in October 20XX that caused physical injuries that have been affecting her lifestyle. She was still receiving treatment for her neck and right ankle injuries that are impacting her activities of daily living and making it difficult for her to participate in the activities she used to enjoy. She was constantly worrying about her injuries and treatments that triggered episodes of anxiety. She was diagnosed with anxiety disorder for which Vistaril was prescribed. [4531-4534]

On June 13, 20XX, Ms. Doe returned to LL Diagnostic Center and Open MRI, where Robert Pope, D.O., obtained an MRI of her neck which revealed reversal of the normal cervical lordosis. There was a mild spur disc complex asymmetric to the right, narrowing of the left neural foramen and hypertrophic uncovertebral joints with central canal of 1 cm diameter at C3-C4 and C4-C5 levels. There was a spur disc complex, hypertrophic uncovertebral joints and mild narrowing of the left and moderate narrowing of the right neural foramen with 7.5 mm narrowed central canal at C5-C6 level. There was also a spur disc complex asymmetric to the central to left paracentral distribution, hypertrophic uncovertebral joints and moderate narrowing of the left and mild narrowing of the right neural foramen with 6 mm narrowed central canal at C6-C7 level. Mild spur disc complex was noted at C7-T1 level as well. [2534-2535]

On June 15, 20XX, Ms. Doe returned to BB Health LaGrange, where Lisa Michelle Nicheols, P.T., examined her for an initial physical therapy evaluation. She complained of pain in her right ankle and rated the severity of her pain as 4-8/10 on a pain scale. She was a caregiver; have not been able to



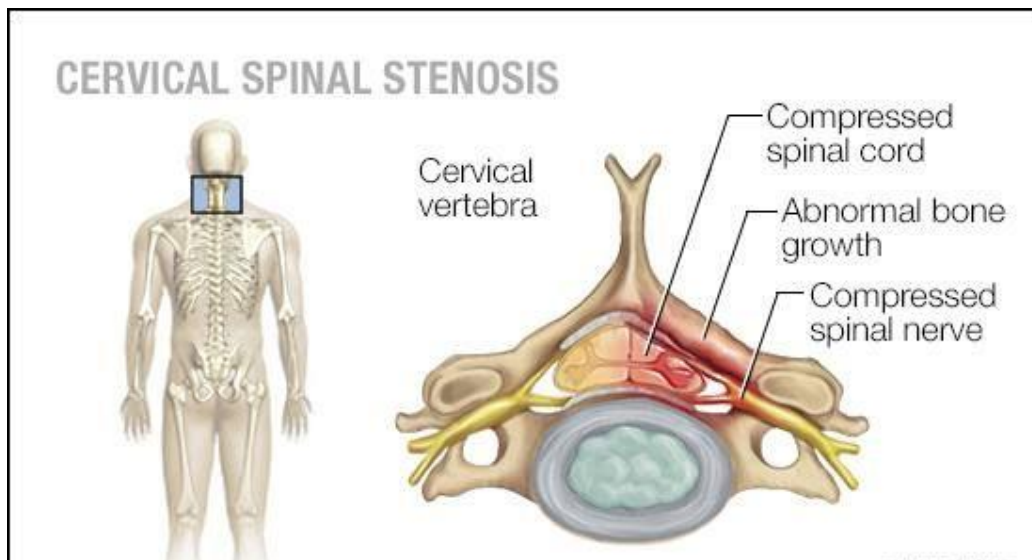
Joe Doe

DOB: mm/dd/yyyy

work since the fall incident. She had difficulty sleeping, performing household chores, shopping, performing recreation activities, playing sports and turning her right ankle. On examination, she had tenderness, decreased range of motion, decreased flexibility, and decreased strength in her right ankle. Orthopedic tests such as Anterior drawer test, Talar tilt test, Thompson test, Homan's sign, Inversion Stress Test and Eversion Stress Test were all positive. Her Lower Extremity Functional Scale score was 16. She was diagnosed with chronic pain of right ankle, right ankle peroneal tendonitis and tear of talofibular ligament of her right lower extremity. She received electrical stimulation, manual therapy, therapeutic procedures, ultrasound and application of heat or cold packs. She was advised to continue receiving physical therapy, two times a week for four weeks. [1479-1497]

On June 22, 20XX, Ms. Doe presented to Steven Reiss, M.D., at BH Medical Group to review the findings of her cervical MRI. She had increased pain in her neck, numbness in her left arm and weakness in her right arm. She had difficulty picking up things due to weakness in her arms. On examination, she had decreased strength in her right arm. An MRI of her neck was reviewed and discussed in detail. She was recommended to obtain a CT myelogram of her neck for further evaluation and treatment. She was advised to follow-up after obtaining CT myelogram of her neck. [1461-1478]

On June 26, 20XX, Ms. Doe presented to Jeffrey Gum, M.D., at NN Healthcare for a second opinion. She complained of pain in her neck and right arm. Her pain worsened with movements and activities. She also had numbness and tingling sensation in the joints of her left hand and right arm. She rated the severity of her pain as 6-8/10 on a pain scale. She had been dropping things and unable to tie her shoes due to myelopathic symptoms. On examination, she had limited and painful range of motion in her neck. An X-ray of her neck revealed cervical spondylosis with severe disc collapse at C6-C7 level. She was diagnosed with cervical spondylosis with radiculopathy, cervical spinal stenosis and right arm weakness after receiving epidural injection. The risk and benefits of the surgical procedure ACDF (Anterior Cervical Decompression and Fusion) at C5-C7 level was discussed. She was recommended to undergo ACDF at C5-C7 levels. [3033-3045]



From June 19, 20XX until July 6, 20XX, Ms. Doe received physical therapy at BB Health LaGrange for the tear of talofibular ligament in her right lower extremity. On July 5, 20XX, she rated the severity of her right ankle pain as 9/10 on a pain scale. On July 6, 20XX, Micah Lee Horn, PTA stated that Ms. Doe did not have any improvement in her symptoms since the beginning of therapy. She was advised to follow-up with her physician for right ankle surgery and discharged from care. Her treatment was comprised moist heat, electrical stimulation, ultrasound and therapeutic procedure. [1525-1536, 1563-1574, 1583-1594, 1602-1611, 1620-1631, 1639-1652]

On July 06, 20XX, Ms. Doe had a follow-up visit with Dr. Lewis at LL Orthopaedic Clinic for the persistent pain in her right ankle and she had no improvement in her symptoms despite receiving physical therapy and taking anti-inflammatories. She rated the severity of her pain as 5/10 on the pain scale. On examination, she had tenderness and swelling in her right ankle. She was diagnosed with persistent right ankle peroneal tendinitis and moderate right gastrocnemius contracture. She was frustrated about her persistent right posterolateral ankle pain. She localized her pain directly over the peroneal tendons. Her right ankle MRI was reviewed, which showed fluid along the peroneal tendon sheath. She had failed over 6 months of exhaustive conservative management, including bracing, anti-inflammatories, immobilization, and physical therapy. She was recommended to undergo surgical exploration, debridement of the peroneal tendons, and repair of any associated split tears. [2851-2853]

On July 11, 20XX, Ms. Doe returned to Dr. Gum at NN Healthcare to evaluate her neck and right arm injuries. She complained of headache due to her neck pain, throbbing sensation in her right arm and numbness in her left hand. On examination, she had limited and painful range of motion in her neck and right upper extremity. She was recommended to have a cervical CT myelogram to evaluate her arm symptoms, facet arthrosis and bony foraminal stenosis. [3824-3833]

On July 19, 20XX, Ms. Doe presented to Mark Miller, M.D., at TT Health Systems-Carrollton Main for the complaints of headaches and numbness in her arms. She was diagnosed with cervical disc disorder at C4-C5 and C6-C7 levels with radiculopathy. Dr. Miller agreed with her neurosurgeon and recommended Ms. Doe to undergo surgery to her cervical spine. An electrocardiogram and labs studies were ordered for surgical clearance. [4702-4706]

On August 01, 20XX, Ms. Doe had a follow-up visit with Dr. Miller at TT Health Systems-Carrollton Main for the complaints of problem with her sleep. She was in her bed and awake for hours at night, due to her neck pain. She was diagnosed with insomnia. Dr. Miller and Ms. Doe discussed a variety of options including changing her medications. The dosage of Trazodone and Hydroxyzine were increased to 100 mg. Melatonin was prescribed and a follow-up was recommended in a month. [4688-4692]

On September 29, 20XX, Ms. Doe returned to Dr. Miller at TT Health Systems-Carrollton Main to evaluate her sleep problems. She stated that Hydroxyzine made her dizzy. She was diagnosed with

Joe Doe

DOB: mm/dd/yyyy

insomnia and anxiety disorder. Ambien was prescribed for sleep problems. A follow-up was recommended in a month. [4680-4684]

On October 13, 20XX, Ms. Doe returned to Dr. Miller at TT Health Systems-Carrollton Main to evaluate her sleep problems. She was able to sleep after taking Ambien, but she had been crying a lot for no reason. She was diagnosed with insomnia for which Restoril was prescribed. [4675-4679]

On October 16, 20XX, Ms. Doe presented to Portia Steele, APRN at NN Healthcare. She noticed that the weakness in her right upper extremity was worsening since her last visit. She was diagnosed with cervical spondylosis with radiculopathy at the C5-C6 and C6-C7 levels and cervical disc herniation. She was recommended to obtain a CT myelogram of her cervical spine for preoperative planning purposes and to evaluate her facet arthrosis. [3848-3857]

On October 24, 20XX, Ms. Doe returned to NN Healthcare, where Malisa Lester, M.D., obtained a CT myelogram of her neck which revealed a shallow left paracentral disc protrusion that indented the ventral thecal sac at C2-C3 level. There was a minimal diffuse disc bulge with mild degenerative uncovertebral, facet joint hypertrophy and slight flattening of the ventral thecal sac (greater on the left than right) at C3-C4 level. There was a minimal diffuse disc bulge with mild to moderate degenerative uncovertebral and facet joint hypertrophy along with bilateral neural foraminal stenosis and slight flattening of the ventral thecal sac at C4-C5 level. There was a mild posterior disc osteophyte complex with a prominent bilobed central component as well as mild to moderate degenerative uncovertebral and facet joint hypertrophy at C5-C6 level. Mild to moderate spinal canal stenosis and flattening of the ventral thecal sac, as well as mild to moderate (right greater than left) bilateral neural foraminal stenosis was also noted at C5-C6 level. There was a mild to moderate posterior disc osteophyte complex with a prominent central/left paracentral component as well as moderate degenerative uncovertebral and facet joint hypertrophy at C6-C7 level. Moderate spinal canal stenosis and slight flattening of the ventral surface of the spinal cord, as well as mild to moderate left and mild right neural foraminal stenosis was noted at C6-C7 level. [3106-3113]

On October 30, 20XX, Ms. Doe had a follow-up visit with Dr. Gum at NN Healthcare to discuss the findings of her CT myelogram. Her myelopathic symptoms had progressively gotten worse since her last visit. The findings were discussed in detail. She was recommended to undergo ACDF at C5-C7 levels with possible C6 corpectomy. [3872-3880]

On February 26, 20XX, Ms. Doe presented to Cindy Haines, N.P., at TT Health Systems-Carrollton Main for the complaints of sleep problems. She would like to change her sleep medications as her ongoing medications did not help her to sleep. Trazodone was prescribed for her insomnia. A follow-up was recommended in two weeks. [3005-3009]

On June 28, 20XX, Ms. Doe returned to Dr. Lewis at LL Orthopaedic Clinic for the exacerbation of her right posterolateral ankle pain. She rated the severity of her pain as 7/10. She had failed over 12 months of exhaustive conservative management including bracing, anti-inflammatories, immobilization,



Joe Doe

DOB: mm/dd/yyyy

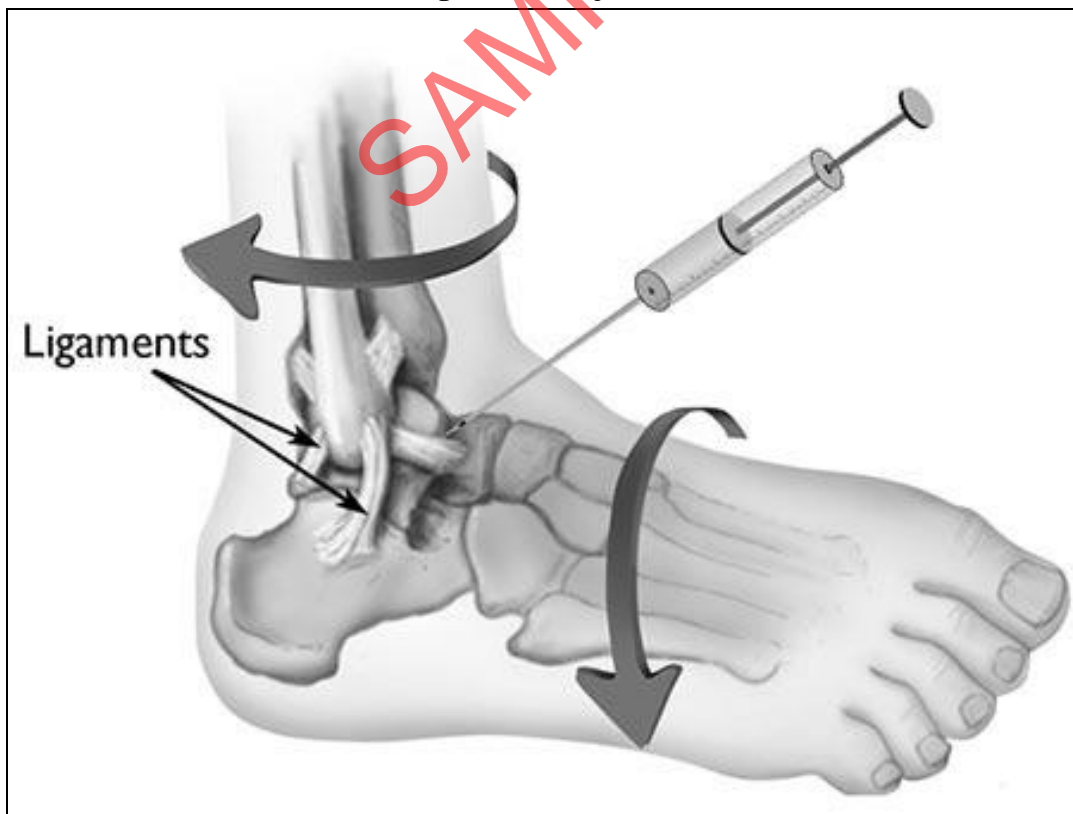
and physical therapy. An MRI of her right ankle was ordered to evaluate any significant tearing or pathology in the peroneal sheath. She was advised to follow-up after the MRI. [2829-2831]

On July 31, 20XX, Ms. Doe had a follow-up visit with Dr. Lewis at LL Orthopaedic Clinic for the persistent right posterolateral ankle pain. An X-ray of her right ankle revealed moderate insertional calcific Achilles tendinitis, small plantar calcaneal spur and healed distal fibular fracture. She was diagnosed with right ankle peroneal tendonitis. She was recommended to obtain an MRI of her right ankle to evaluate any significant tearing or pathology in the peroneal sheath. She was advised to follow-up after the MRI. [2826-2828]

On August 03, 20XX, Ms. Doe returned to LL Orthopaedic Clinic, where John Rothpletz, M.D., obtained an MRI of her right ankle which revealed degenerative changes along her anterior hind foot. [2821-2822]

On August 06, 20XX, Ms. Doe had a follow-up visit with Dr. Lewis at LL Orthopaedic Clinic to discuss the findings of her right ankle MRI. After discussing the MRI findings, Dr. Lewis administered an injection to Ms. Doe's right ankle. She was advised to consider peroneal tendon exploration, if her pain was persistent. [2844-2846]

Right Ankle Injection



Joe Doe

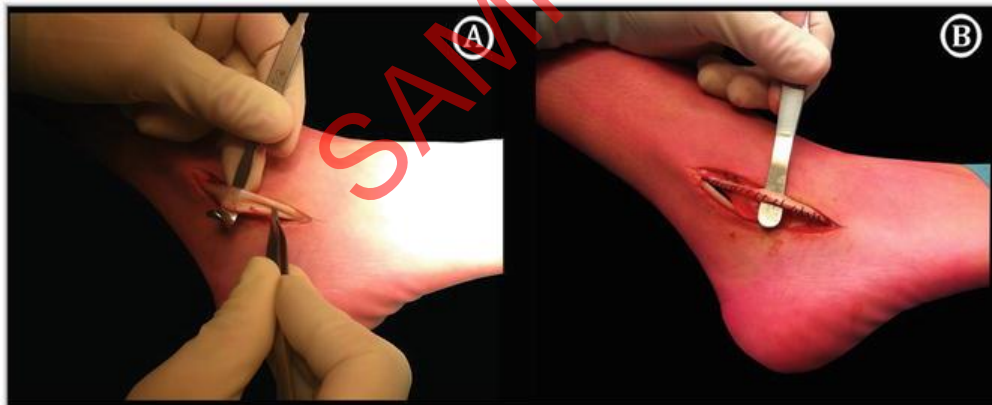
DOB: mm/dd/yyyy

On August 09, 20XX, Ms. Doe returned to BB Health LaGrange, where Ryan Patrick Currier, M.D., obtained an ultrasound of her neck soft tissue which revealed enlarged level one cervical lymph nodes. Inflammatory/infectious etiologies were considered to be the most common cause, however, a close follow-up was recommended to differentiate from a potentially neoplastic process. [2180-2181]

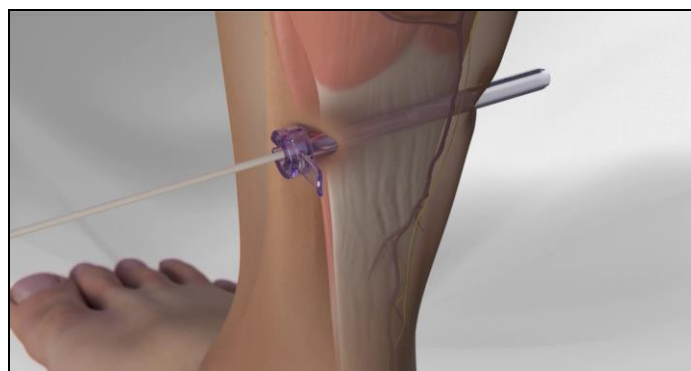
On August 20, 20XX, Ms. Doe had a follow-up visit with Dr. Lewis at LL Orthopaedic Clinic. Her pain significantly improved for approximately two hours after receiving injection and then again, she experienced pain in her right ankle. On examination, she had tenderness and swelling in her right ankle. She also had an antalgic gait. She was recommended to undergo an open peroneal tendon exploration and debridement along with gastrocnemius recession as her symptoms did not improve after receiving right ankle injection. [2841-2843]

On September 10, 20XX, Ms. Doe presented to PP Medical Center Regional Hospital, where Dr. Lewis performed an open debridement, tenolysis, tenosynovectomy of peroneus brevis with primary repair of split tear, open debridement and tenolysis of right peroneus longus along with right gastrocnemius recession. Percocet and Aspirin were prescribed for pain relief and DVT prophylaxis. She was recommended not to bear weight on her right ankle and to elevate her right leg and move around once an hour, while awake, to help to minimize the risk of blood clots. [2817-2820]

Tenosynovitis of Peroneus Brevis



Gastrocnemius Recession



Joe Doe

DOB: mm/dd/yyyy

On September 15, 20XX, Ms. Doe presented to Susan Sanford, APRN at TT Health Systems-Carrollton Main for a post-operative follow-up. She had pain in her right ankle and requested pain medications. She was advised to follow-up with Dr. Miller for a dressing change. [4471-4475]

On September 20, 20XX, Ms. Doe had a follow-up visit with Dr. Lewis at LL Orthopaedic Clinic for her splint irritation. On examination, she had post-operative swelling in her right ankle. Her splint was removed and a tall boot was provided for ambulation. She was advised not to bear weight on her right ankle and follow-up in the following week for suture removal. [2982-2983]

On September 25, 20XX, Ms. Doe returned to Dr. Lewis at LL Orthopaedic Clinic. She was doing well in the boot. Her staples were removed. She was advised not to bear weight on her right ankle and begin to attend physical therapy to work on ankle range of motion, and peroneal tendon motion. A follow-up was recommended in four weeks. [2986-2987]

On October 03, 20XX, Ms. Doe presented to Sarah Patterson, P.T., at BB Health LaGrange for an initial physical therapy evaluation. She complained of pain in her right ankle and posterior knee area. She was unable to perform all activities of daily living and self care activities. She was also unable to don/doff her boot and shower. Her spouse had to assist her for all these activities. She had been using wheelchair for ambulation. On examination, she had ecchymosis, decreased range of motion and decreased strength in her right lateral ankle. She was diagnosed with tear of talofibular ligament of her right lower extremity and right peroneal tendonitis. She received electrical stimulation, kinesiotape and ice packs were applied to ease her symptoms. She was advised to continue receiving physical therapy, two times a week for eight weeks. Her treatment plan included therapeutic procedure, gait training, application of hot or cold packs, electrical stimulation, and manual therapy. [1706-1718]

On October 09, 20XX, Ms. Doe was seen by Dr. Miller at TT Health Systems-Carrollton Main to evaluate her neck pain. Lab studies were ordered. She was advised to follow-up after her neck surgery. [4465-4470]

On October 22, 20XX, Ms. Doe returned to Dr. Lewis at LL Orthopaedic Clinic. She was wearing a boot and had been bearing weight as tolerated. She had minimal pain in her right ankle and was pleased with her progress. She was advised to start using lace-up brace and follow-up in six weeks. [2839-2840]

On the same day, Ms. Doe had a follow-up visit with Dr. Gum at NN Healthcare. She had the same symptoms in her neck as she did last year. She also had myelopathic symptoms such as dropping things, difficulty with handling buttons and zippers and loss of fine motor skills. After a long discussion, she was recommended to undergo ACDF at C5-C7 levels with possible C6 corpectomy. [3267-3277]

From October 9, 20XX until November 21, 20XX, Ms. Doe received physical therapy at BB Health LaGrange for her right ankle pain. On October 16, 20XX, she complained of increased edema and



Joe Doe

DOB: mm/dd/yyyy

soreness in her right ankle. On October 24, 20XX, she had tenderness surrounding her incision site. On November 8, 20XX, she had pain at night and rated the severity of her pain as 8/10 on a pain scale. On November 21, 20XX, she had increased discomfort in her right ankle with prolonged weight bearing. She was advised to perform home exercise program. Her treatment was comprised of electrical stimulation, therapeutic exercises, kinesiotape and application of ice packs. [1739-1751]

On December 04, 20XX, Ms. Doe was seen by Dr. Lewis at LL Orthopaedic Clinic. She was pleased with her progress. Her right ankle felt stable and strong. She had persistent neuritic symptoms in her right lateral foot. Compounding cream was prescribed for her neuritis. She was advised to perform activities as tolerated and follow-up in twelve weeks for a final clinical check-up. [2832-2834]

On January 23, 20XX, Ms. Doe presented to Guy Lerner, M.D., and Susan Steitz, APRN for an evaluation of her neck pain. She had radicular pain to her arms with paresthesias and weakness in her right arm. She began having symptoms in her neck and right arm since the fall from 20XX. She had difficulty bending forward, lifting her head up, turning her head while she was looking over her shoulder to drive, lifting heavy items, unable to do laundry and cleaning, and unable to pull clothes out of the washing machine, with her right arm. She was also unable to perform any outside work such as gardening, mowing and driving long distances. She had pain that increased while holding her cell phone. She was recommended to undergo surgery to her cervical spine. Norco was prescribed for pain relief. She was advised to follow-up in a month. [2376-2391]

On February 27, 20XX, Ms. Doe returned to Dr. Lerner and Susan Steitz, APRN for the complaints of persistent pain in her neck and right arm. She had been taking Ibuprofen for pain relief. She rated the severity of her pain as 6/10 on a pain scale. She was unable to participate in her favorite hobbies and was unable to read books or look at her cell phone. She had no benefits from physical therapy. She was advised to continue taking Norco until she gets an approval for her neck surgery. [2392-2406]

On March 05, 20XX, Ms. Doe was seen by Dr. Lewis at LL Orthopaedic Clinic to evaluate her right ankle. She was doing well. She was advised to perform activities as tolerated and follow-up as needed. [2823-2825]

On April 24, 20XX, Ms. Doe returned to Dr. Lerner and Susan Steitz, APRN for the complaints of persistent pain in her neck and right arm. She was advised to continue taking Norco until she gets an approval for her neck surgery. [2407-2421]

On April 30, 20XX, Ms. Doe had a follow-up visit with Dr. Gum at NN Healthcare. Her anterior C6 vertebrectomy and C5-C7 fusion with Dr. Harpring was scheduled on May 17, 20XX. [3619-3627]

On May 17, 20XX, Ms. Doe presented to Norton Hospital, where John Harpring, M.D., performed an anterior C6 vertebrectomy (approximately 85% of the C6 vertebral body resected) which was followed by placement of a strut graft fusion and anterior cervical plate fusion from C5 to C7,

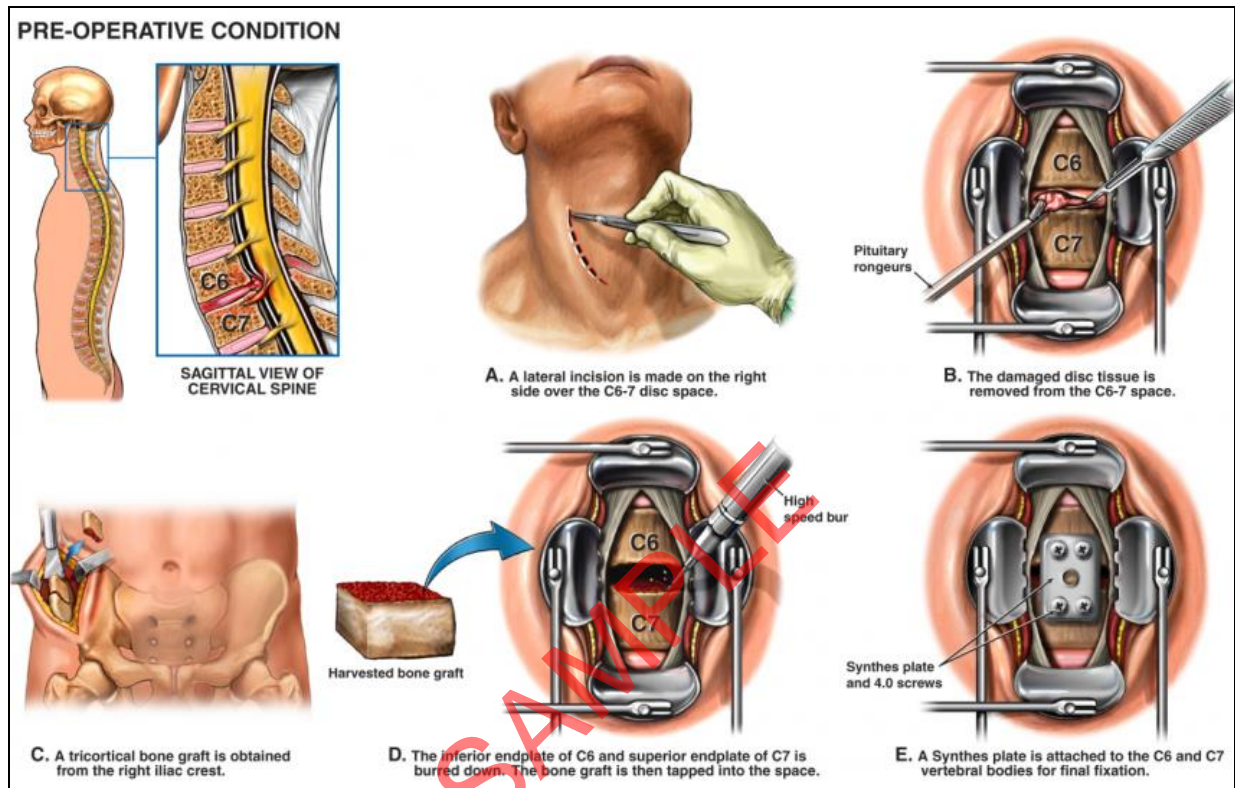


Joe Doe

DOB: mm/dd/yyyy

performed by Dr. Gum. Intra-operative X-rays of her neck were obtained for monitoring the procedure. [3553-3557]

Anterior Cervical Fusion



On the same day, Ms. Doe was examined by Ryan Fields, M.D., for a post-operative evaluation. She was advised to continue taking her home medications for her hypertension, hypokalemia, type II diabetes, and cardiac murmur. [3563-3564]

On May 18, 20XX, Ms. Doe was examined by Kaylee Bui, APRN for a routine check-up. She was doing well. An X-ray of her neck was obtained to check her hardware. Her drain was removed and she was advised to mobilize her neck. [3559-3562]

On the same day, Dr. Fields examined Ms. Doe for a routine check-up. She was doing well. Her sugar level had increased due to steroids. [3562]

Later, on the same day, Ms. Doe was seen by Dr. Harpring. After a complete examination. Flexeril, Norco and Norvasc were prescribed and she was discharged home. [3548-3550]

On May 26, 20XX, Ms. Doe returned to the Emergency Department of NN Healthcare, where Jennifer Janes, APRN examined her for the complaints of difficulty swallowing. She described it as a "bouncy ball going up and down in her throat". She had difficulty swallowing larger pills which required

Joe Doe

DOB: mm/dd/yyyy

multiple attempts to swallow. She had only eaten pudding, soup, and applesauce since discharge. A CT of her neck dated May 25, 20XX revealed postoperative changes from C5 to C7 with relatively mild prevertebral soft tissue swelling and mild hematoma remnant along the incision site in the right side of her neck. Solu-cortef was prescribed. She was advised to stay Nil Per Oral (NPO) for observation and monitor her steroid induced hyperglycemia. She was planned to discharge after steroid taper. [3571-3574]

On May 27, 20XX, Ms. Doe was examined by Kaylee Bui, APRN. Her issues with swallowing improved after receiving steroids. [3575-3577]

Later, on the same day, Ms. Doe was seen by Scot Rolly, M.D., at NN Healthcare. She responded well to empiric treatment with systemic steroids. She was advised to continue steroid taper and follow-up with her neurosurgeon as scheduled in June. [3567-3570]

On May 28, 20XX, Ms. Doe presented to Tina Woodson, APRN at NN Healthcare to evaluate her neck. She was swallowing food with soft consistencies without difficulty. On examination, she had one cm hematoma along the incision line. She was advised to keep the height of her bed elevated, apply ice packs to her neck and continue taking medications. Valium was prescribed for her anxiety and to relax her muscles. She was advised to follow-up in two weeks. [3664-3673]

On June 11, 20XX, Ms. Doe returned to Tina Woodson, APRN at NN Healthcare for a follow-up. She was doing well and wearing her cervical collar. She was advised to follow-up in six months for a routine check-up. [3699-3707]

On July 18, 20XX, Ms. Doe had a follow-up visit with Dr. Lerner and Katie Collins, APRN. She complained of pain in her neck throughout the day. She had difficulty turning her neck on either sides and looking down. She was also experiencing anxiety and requested a prescription for Ativan. COMM (Common Opioid Misuse Measure) test was performed which revealed Ms. Doe was at risk for opioid misuse. The appropriate usage of pain medication was discussed. [2423-2438]

On August 14, 20XX, Ms. Doe presented to Heather Ruccio, P.A., at NN Healthcare. She felt fullness in the front of her neck while leaning forward. After a complete examination, she was advised to continue taking her current medications and massage her incision to help with the fullness of her neck. A follow-up was recommended in four weeks. [3744-3750]

On September 17, 20XX, Ms. Doe had a follow-up visit with Dr. Lerner and Katie Collins, APRN. She started experiencing pain in her neck that was worsened by turning her neck side to side and backwards. She rated the severity of pain as 7/10 on a pain scale. Treatment options such as facet injections and physical therapy were discussed. She would like to discuss her treatment options with Dr. Harpring and Dr. Gum. She was advised to continue taking Norco for pain relief. [2439-2454]

On October 17, 20XX, Ms. Doe visited Dr. Harpring at NN Neuroscience. Dr. Harpring stated that her prognosis was undetermined because she had reached maximum medical improvement. It



Joe Doe

DOB: mm/dd/yyyy

appeared from review of the records and Ms. Doe's history that she had a pre-existing dormant condition which was brought into a disabling reality by the fall on October 4, 20XX. [3312-3313]

On November 12, 20XX, Ms. Doe had a follow-up visit with Dr. Lerner for the complaints of persistent pain in her neck. She rated the severity of her pain as 9/10 on a pain scale. After a complete examination, she was advised to continue taking her pain medications. [2458-2474]

On December 12, 20XX, Ms. Doe returned to Heather Ruccio, P.A., at NN Healthcare. She continued to have pain in the back of her neck along with right arm paresthesias. She was recommended to continue to perform activities and not to lift more than 20 lbs. She was advised to consider obtaining a CT of her neck, if she continued to have pain in her neck. A follow-up was recommended in three to four months. [3763-3772]

SAMPLE

